

EFFICACY AND SAFETY OF A HYDROCORTISONE ACEPONATE CONTAINING EAR SPRAY SOLUTION IN DOGS WITH ERYTHEMATO-CERUMINOUS OTITIS EXTERNA: A RANDOMISED, MULTICENTRIC, SINGLE-BLINDED, CONTROLLED TRIAL



Delphine Rigaut¹; Philippe Briantais¹; Peter Pan²; Pierre Jasmin^{1*}; Alice Bidaud¹
¹Virbac SA, Carros, France; ²Virbac Taiwan, Taipei, Taiwan; *pierre.jasmin@virbac.com

Introduction

Erythematoto-ceruminous otitis externa (ECO) is frequently diagnosed in dogs with an allergic skin disease in which microbial overgrowths are commonly associated¹⁻⁴. Oral or topical glucocorticoids have already demonstrated efficacy to reduce skin lesions in atopic dogs or clinical signs of allergic otitis externa in single-use⁵⁻⁸. This study compares the efficacy and safety of an ear spray only containing hydrocortisone aceponate glucocorticoid diester (HCA) to an otic formulation containing a prednisolone-miconazole-polymyxin B combination (CTRL) in dogs with ECO.

Methods

On D0, dogs with ECO with an OTIS-3 score ≥ 5 and cytological confirmation of bacteria and/or yeast, were randomly allocated (1:1) to HCA or CTRL group and treated for 7-to-14 days, as needed. A total of 97 and 104 dogs were respectively included in the HCA and CTRL group. At D0, D7, D14, D28 and D42, OTIS-3, pain, pruritus and cytological scores were graded. Treatment success was defined as OTIS-3 ≤ 3 on D28. The overall response to treatment was also assessed.

Results

All clinical parameters and cytological scores decreased rapidly and similarly without any significant difference at any time between treatment groups.

As early as D7, a significant reduction by close to half of mean OTIS-3 scores (HCA: $48.9 \pm 26.7\%$; CTRL: $49.2 \pm 24.9\%$) was noticed for both treatment groups. Similarly, mean OTIS-3 scores were reduced by almost three-fourths on the following visits (Figure 1). HCA ear spray was found non inferior to the CTRL product at D28.

The owner-assessed VAS (0-10) pain score and VAS (0-10) pruritus score, were halved as soon as D5 in both groups. Pruritus scores were reduced by 39% and 36% on D3 in the HCA group and CTRL group respectively, by 57% and 55% on D5, by 69% and 65% on D7 and by 82% and 81% on D14 (Figure 2).

On D28 treatment success was reached in 93.5% and 89.2% of the HCA and CTRL dogs, respectively (Figure 3).

According to the investigator's pain assessment (0-3), complete relief of pain was obtained on D14 in 83.2% and 69.6% of the dogs from the HCA and CTRL groups, respectively.

Analysis of the cytological scores, both on bacteria and yeast, showed a similar decrease in both groups (Figure 4).

A good-to-excellent response to treatment was reported in over 90% of dogs of both groups as soon as D14 by vets and owners. Finally, the treatment was considered safe for all dogs.

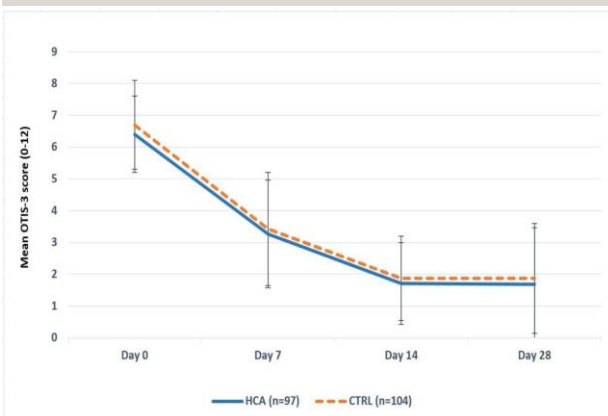


Figure 1: Mean Otis-3 score evolution over time.

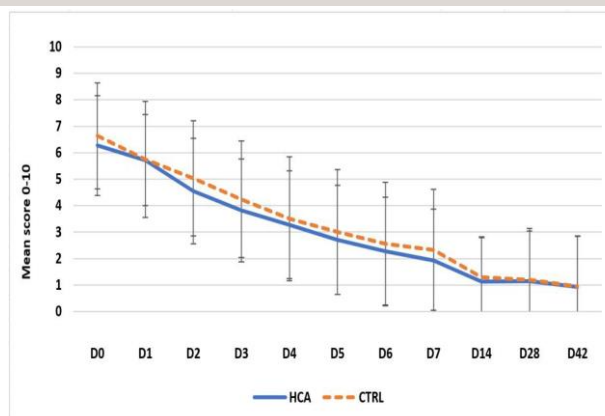


Figure 2: Mean pruritus score evolution over time.

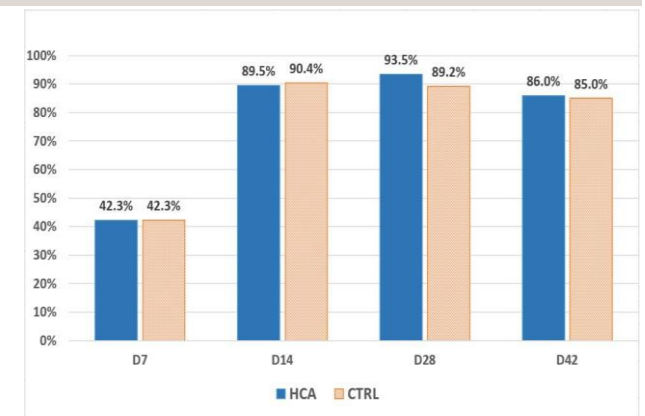


Figure 3: Percentage of dogs with "treatment success" at follow-up visits.

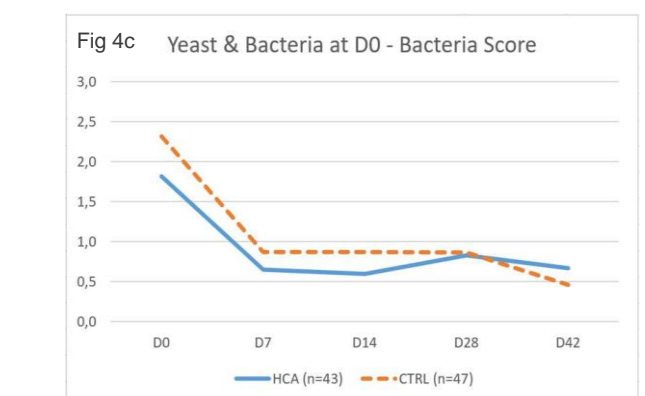
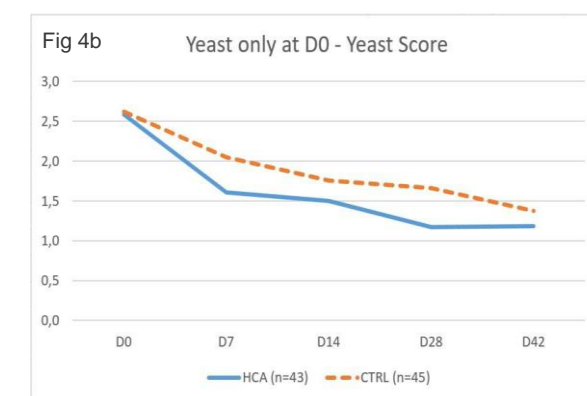
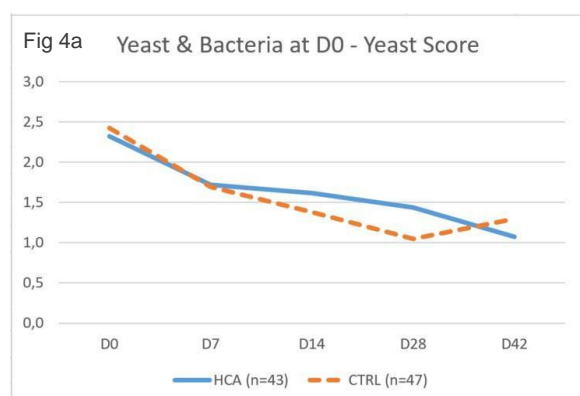


Figure 4 : Evolution of yeast and bacteria cytological scores (0 to 4+) over time (depending on bacteria and/or yeast overgrowth at Day 0).
 Fig 4a : Yeast and bacteria at D0 – Yeast score. / Fig 4b : Yeast only at D0 – Yeast score. / Fig 4c : Yeast and bacteria at D0 – Bacteria score.

Conclusion

A 7-to-14-day ear topical application of HCA corticosteroid alone to dogs with ECO associated with bacteria and/or yeast overgrowth was safe and actually improved the clinical and cytological scores in the same way as the CTRL treatment product containing an antifungal and an antibiotic in addition to a corticosteroid. These results suggest that the addition of antimicrobials might not be necessary in first intention, and that targeting inflammation without using unnecessary antimicrobials can be recommended as a first-line treatment of ECO in dogs. To prevent further relapses of ECO the identification and management of the underlying cause, such as an allergic skin disease, should be run.



References

1. Carlotti DN et al. 1997. *Prat Med Chir Anim Comp.* 1997; 32: 243-257.
2. Bensignor E et Al. *Prat Med Chir Anim Comp.* 2000; 35: 405-414.
3. Aymeric-Cuingnart E et Al. *Rev Vet Clin.* 2018; 53: 3-9.
4. Campbell JJ et Al. *Vet Dermatol.* 2010; 21: 619-625.
5. Olivry T et al. 2003. *Vet Dermatol* 14: 121-146.
6. Olivry T et al. 2010. *Vet Dermatol* 21: 4-22.
7. Olivry T et al. 2013. *Vet Dermatol* 24: 97-117.e25-6.
8. Bergvall KE et al. 2017. *Vet Dermatol.* 28: 535

